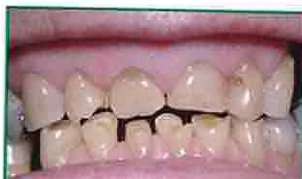
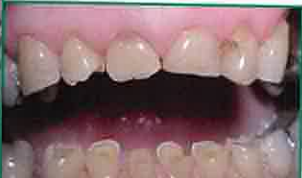
# EROSION MOUSSE

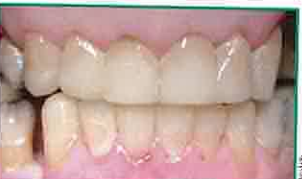Prof. Laurie Walsh, University of Queensland



Many teeth had become worn, chipped and very sensitive.



The home care program comprised an application of GC Tooth Mousse each night, in combination with sodium bicarbonate mouthrinses after each meal and again after any episodes of reflux.



After the buildups the teeth look and feel much better.

Prof. Laurie Walsh

Betty is 64 years old and wanted to improve the function and appearance of her teeth. Many teeth had become worn, chipped and very sensitive. Betty had suffered from gastric reflux for some years, and the condition had recently become worse because of her use of a particular drug for an arthritic condition.

The approach taken was to seek help from Betty's doctor and to commence a home care program comprising GC Tooth Mousse applied each night, in combination with sodium bicarbonate mouthrinses after each meal and again after any episodes of reflux. This treatment quickly reduced the symptoms of sensitivity and began the process of remineralizing the depleted tooth structure.

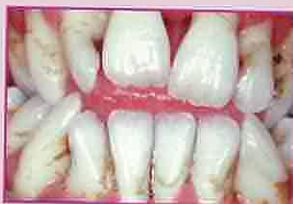After six weeks on the home care program, tooth buildups were undertaken on top of the existing tooth structure.

The result of this treatment has been conservation of the existing tooth structure, with improved look and function. GC Tooth Mousse is very good at arresting the disease process and creating a sound foundation for restorative work.

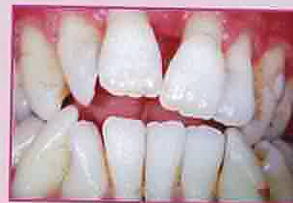# GERODONTIC MOUSSE

Prof. Laurie Walsh, University of Queensland

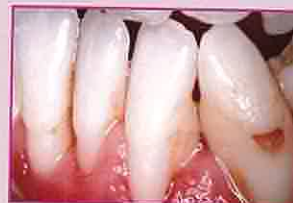Elderly patients, like Antonio, with dry mouth symptoms linked to their medical conditions or their medications are particularly prone to caries. By increasing calcium in saliva and dental plaque, GC Tooth Mousse can reduce problems and drive remineralization.



Antonio has type II diabetes. His diabetic condition was undiagnosed until recently, and was a major contributor to his low saliva levels which have caused problems with his teeth.




After starting a home care program to promote remineralization and a series of appointments for cleaning and restorative work, the situation has improved. Daily use of GC Tooth Mousse, used in conjunction with a triclosan-releasing toothpaste (Colgate Total™) and flossing, is a key part of Antonio's home care over the long term.



The teeth now have much less plaque and are now hypermineralized offering greater protection against further problems.

Prof. Laurie Walsh




GC Asia Dental Pte. Ltd  
Changi Logistics Centre  
19 Loyang Way #06-27  
Singapore 508724  
T 65 + 6546 7588  
F 65 + 6546 7577  
www.gcasia.info



©GC Corporation 2006.

Recaldent® is used under licence from Recaldent Pty. Limited. Recaldent® CPP-ACP is derived from milk casein and is lactose free. It should not be used on patients with milk protein allergies. CPP-ACP technology has related patents or patents pending in Australia, NZ, Europe, Canada and USA.



# Tooth Mousse

CAN HELP YOUR TEETH  
THROUGHOUT YOUR LIFE

CHILDREN

ADULTS

SENIORS

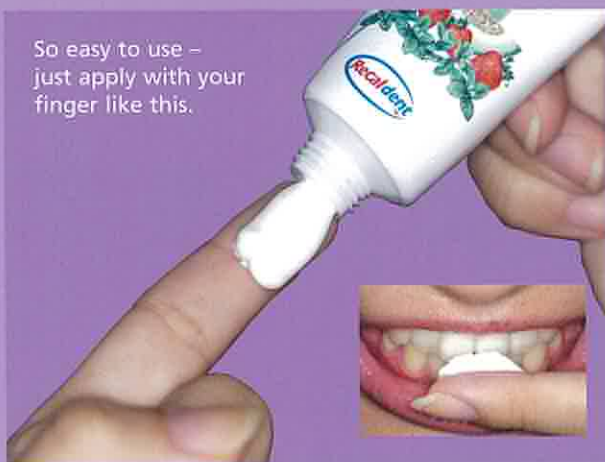Since its introduction, GC Tooth Mousse has quickly become a firm favourite as a topical coating for teeth with a myriad of uses.

GC Tooth Mousse is a water based, sugar free creme containing Recaldent® CPP-ACP, which is derived from cows' milk. This booklet shows just some of the applications for Tooth Mousse.

**For more information, please seek professional advice.**

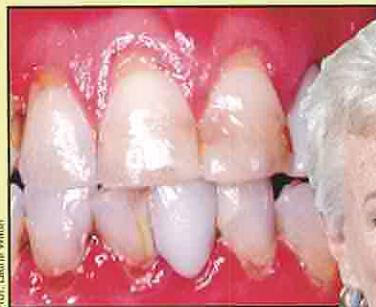

So easy to use – just apply with your finger like this.



## XEROSTOMIA MOUSSE

Prof. Laurie Walsh, University of Queensland



Prof. Laurie Walsh



Helen, a 55 year old school principal, complained of marked sensitivity to cold and air affecting many of the root surfaces of her teeth. This problem began six months ago but has become more severe over time. She has also noticed small cavities appearing on some of the root surfaces. Coincidentally, Helen has noticed increasing dryness in both her mouth and eyes. Her general health is good and she has no other health problems. Clinical examination revealed that some teeth have exposed root surfaces and are therefore extremely sensitive. Root surface caries is present on the lower back teeth. Saliva testing also revealed problems. A lifestyle analysis revealed that Helen did not consume either caffeine or alcohol, and had a water intake of more than two litres per day. The combination of poor saliva and eye dryness in a female patient of this age is suggestive of primary Sjögren's syndrome, which was confirmed by further tests. In light of her ongoing caries and erosion problems, Helen's home care program included GC Tooth Mousse twice daily, a saliva substitute, and intermittent chlorhexidine gel therapy once per week to suppress harmful bacteria. After filling her cavities, Helen was then enrolled in a three-monthly maintenance program to ensure regular review of her status and to provide ongoing fluoride varnish applications to the at-risk tooth surfaces.

## TOOTH WEAR MOUSSE

Prof. Ian Meyers, University of Queensland

Joe, 67 years old, had a long history of tooth structure loss with little being done to restore form and function. His lifestyle characteristics included:

- Large daily consumption of fruits and past moderate consumption of black cola drinks
- Grinding of teeth at night in the past

Joe's main complaints were sharp edges on teeth and poor appearance. Previous treatment for sensitivity included some restorative work and some endodontic treatments. While the bulk of his tooth wear occurred in the past and he had no current tooth sensitivity, demineralization and tooth wear were still active. Joe was on many medications – adversely affecting his saliva. To help improve Joe's oral condition a home care program was designed to control his problems.

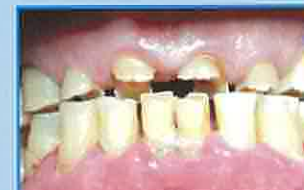The initial treatment was to reduce dietary acids and increase water consumption. Joe was also advised:

- To use a high fluoride content toothpaste (5000ppm)
- To use a bicarbonate mouth rinse after episodes of gastric reflux and apply Tooth Mousse at least once daily but more frequently after episodes of reflux

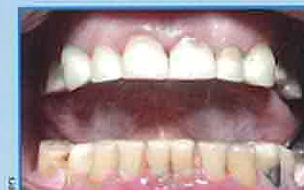The back teeth were initially restored to protect the remaining tooth structure and reduce the sharpness of the teeth.

There was improvement in his saliva, but due to the multiple medications Joe was taking, it was considered that further improvements may not occur.

He was also advised to continue with his home care treatment due to the slightly acidic nature of his saliva and the need for constant monitoring.



Severe tooth structure loss accelerated by the acidic oral environment and poor quality saliva



Full composite resin crowns placed over the prepared teeth

Prof. Ian Meyers

